



EMS CONSORTIUM

EMS Approach To The Patient With A Headache

Types of Headaches

Primary

- Migraine
- Tension
- Cluster

Secondary

- Infection
- Trauma
- Vascular
- Tumor
- Toxicity


A piece of brown, textured paper is shown with a jagged tear. Through the tear, the word "HISTORY" is printed in a bold, black, serif font on a white background. The paper is slightly wrinkled and has a natural, fibrous texture.

HISTORY

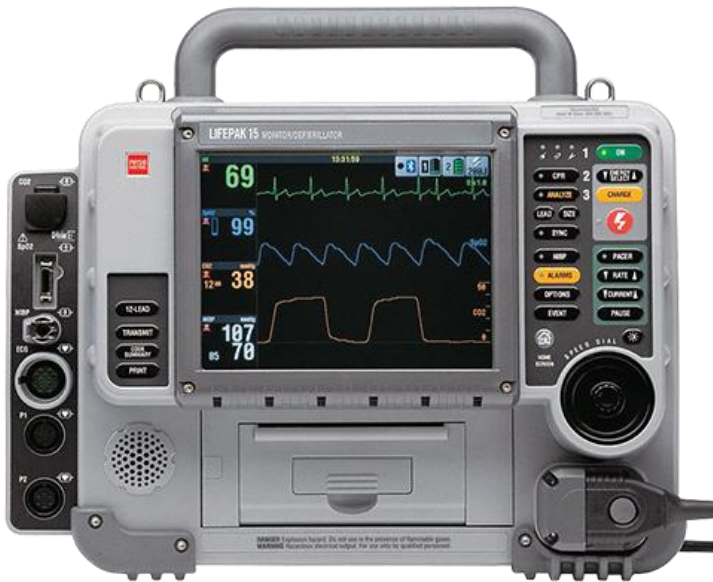History and Physical Exam are VERY Important

Ask About These Red Flags

1. Recent Head Trauma
2. History of cancer
3. Bleeding/clotting disorder
4. Associated Symptoms:
 - Fever , Neck stiffness
 - Vision changes
 - New neuro symptoms
5. Onset and progression of pain





Evaluation of Headache





Cincinnati Pre-hospital Stroke Scale

1. FACIAL DROOP: Have patient show teeth or smile.

 <p>Normal: both sides of the face move equally</p>	 <p>Abnormal: one side of face does not move as well as the other side</p>
--	--

2. ARM DRIFT: Patient closes eyes & holds both arms out for 10 sec.

 <p>Normal: both arms move the same or both arms do not move at all</p>	 <p>Abnormal: one arm does not move or drifts down compared to the other</p>
---	--

3. ABNORMAL SPEECH: Have the patient say "you can't teach an old dog new tricks."

Normal: patient uses correct words with no slurring **Abnormal:** patient slurs words, uses the wrong words, or is unable to speak

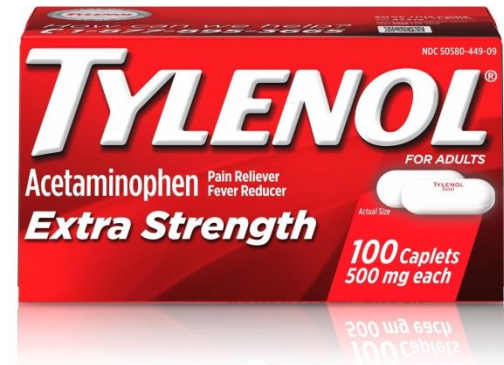INTERPRETATION: If any 1 of these 3 signs is abnormal, the probability of a stroke is 72%.

**Perform Cincinnati Stroke Scale
When Appropriate**

Vital signs are vital

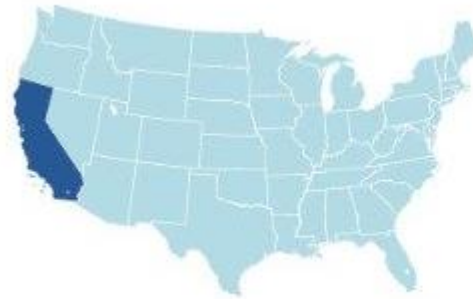EMS Treatment of Headache

- Airway and Oxygen if indicated
- Pain control
 - Narcotics?
 - No NSAIDS
 - Tylenol
 - Ketamine
 - Droperidol
- Anti-emetics
- IV fluids



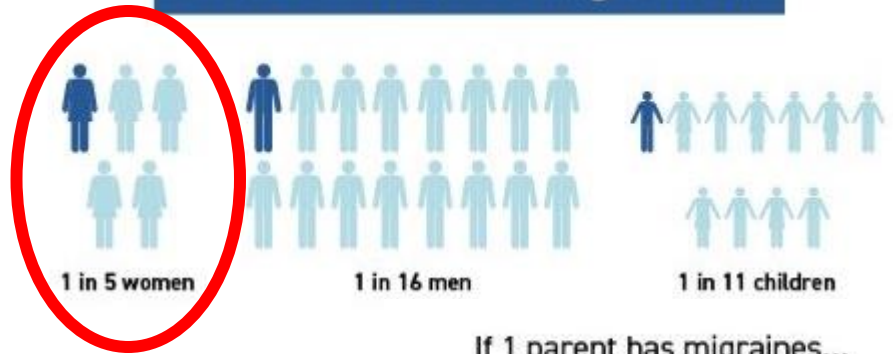
Migraines

- Throbbing Pain
- Usually unilateral
- Associated with:
 - Nausea/vomiting
 - Photophobia
 - Aura



12% of people in the U.S. suffer from migraines. That's equal to the population of California!

How common are migraines?



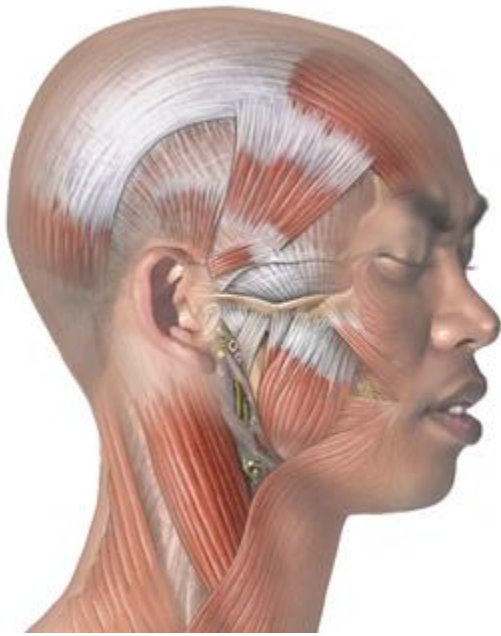If 1 parent has migraines...



“Is This Like Your Usual Headache?”

Tension Headaches

Tight band-like pain on both sides of the head or neck, usually tender to touch

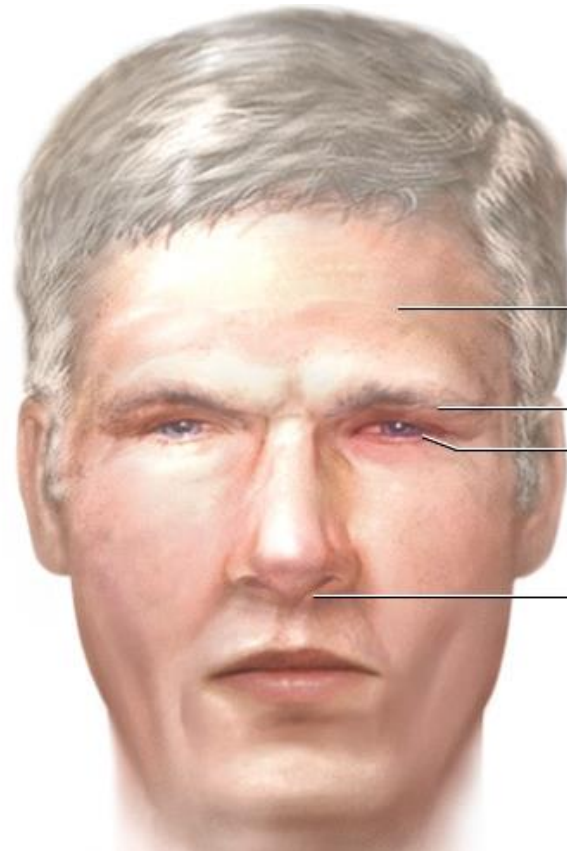


Muscle tension in the face, neck, and shoulders may cause tension headache



Cluster Headaches

More common in males 20-40 years old that smoke
Occur in clusters, episodes usually last <1 hour at a time



Cluster headache symptoms occur on one side of the head and may include:

Sweating

Conjunctival Injection

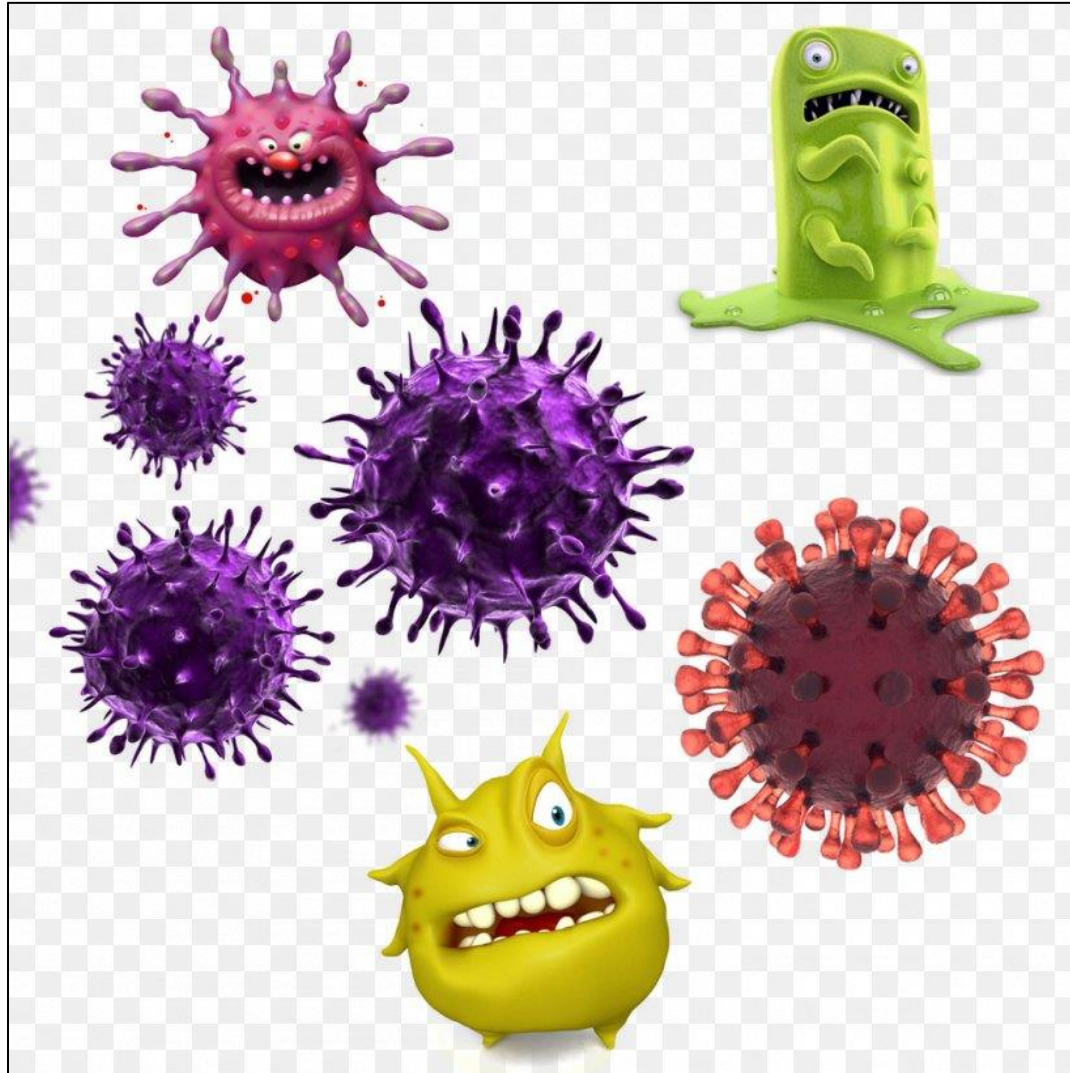
Tearing, eyelid swelling

Nasal Congestion

Facial Flushing

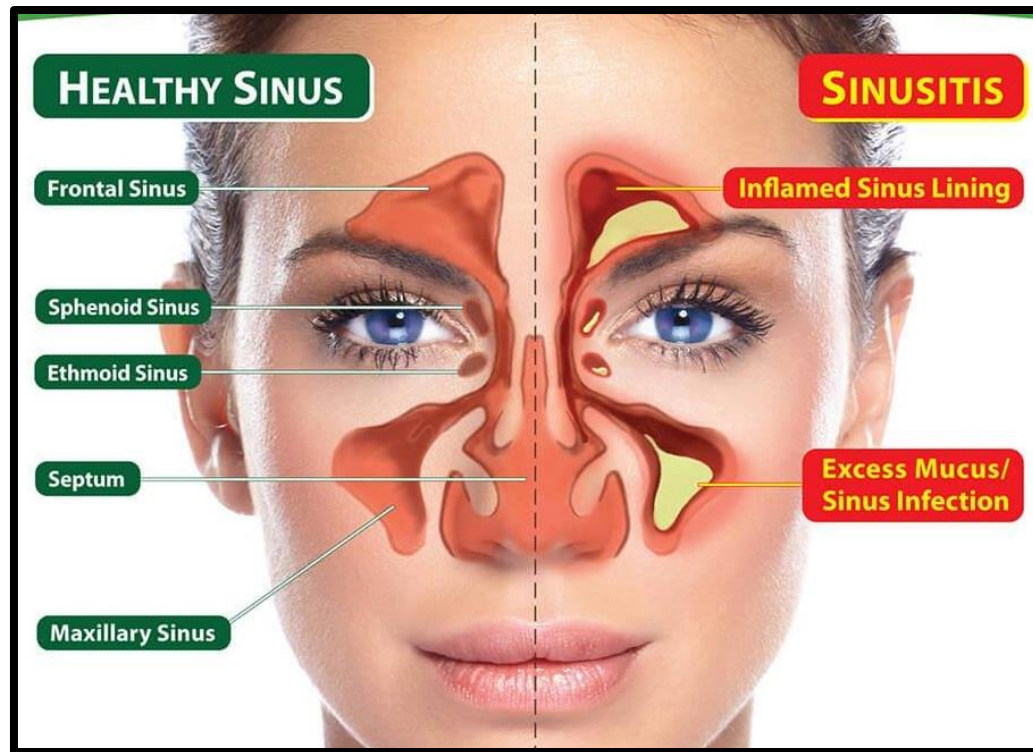
Treat with Oxygen

Infectious Causes of Headache



Sinusitis

- Fluid builds in sinus cavities and can get infected
- Usually caused by allergies, smoking, URI, or virus

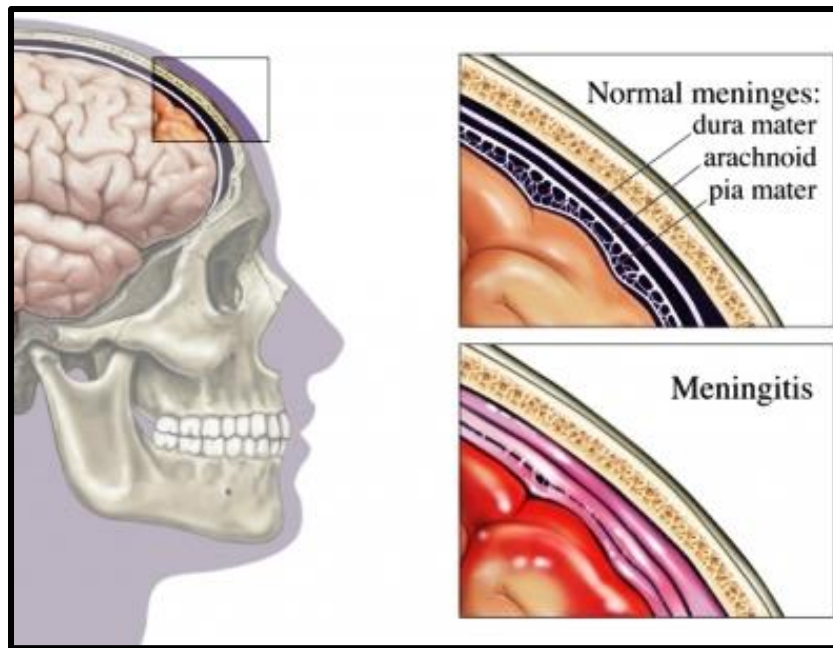


EMS Treatment is supportive care

Meningitis

Infection in the lining of the brain and spinal cord

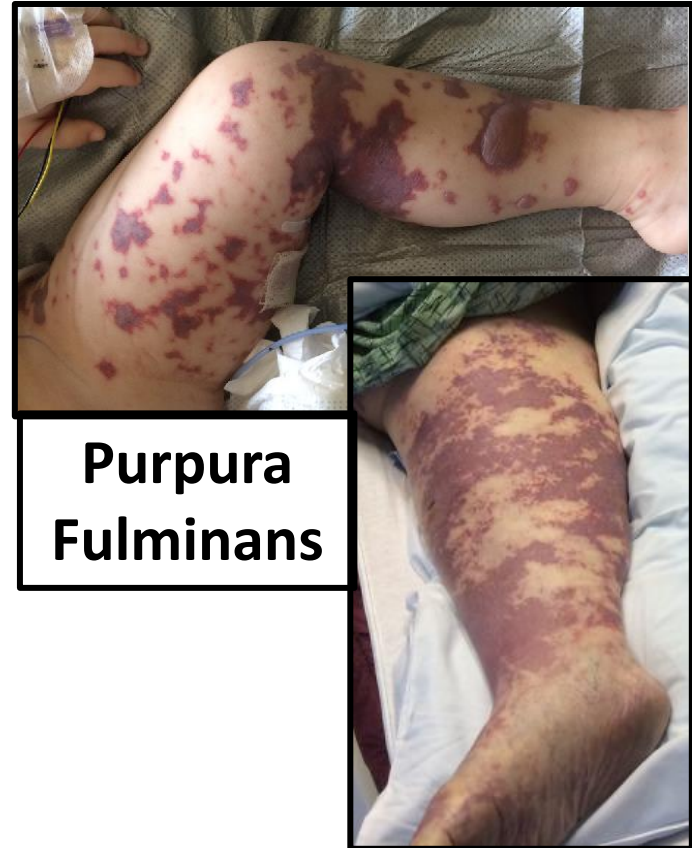- Can be viral, bacterial, or fungal



**Fever, Headache, Stiff Neck, Altered
Mental Status**

Bacterial Meningitis

- High Mortality
 - Brain damage
 - Hearing loss
- Use Full PPE
 - N95 mask
 - Eye shield
 - Gown



Can cause seizures and septic shock

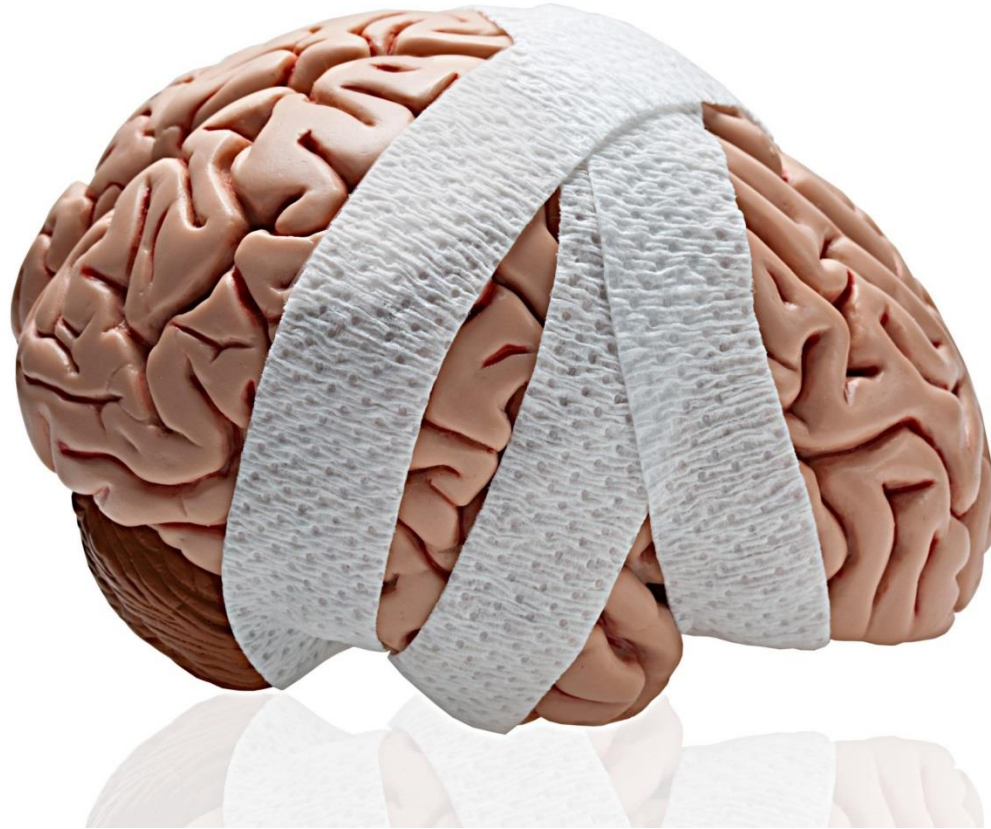Tick or Mosquito Born Diseases

Can cause fever, headache, joint pain, rash



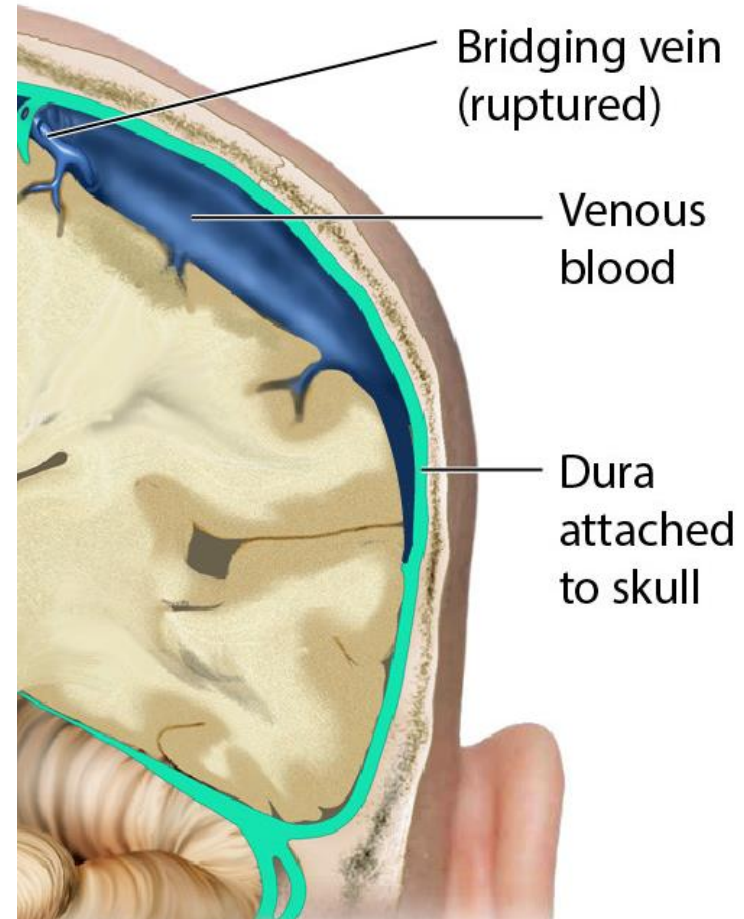
Ask about recent camping, hunting, or outdoor activities

Traumatic Causes Of Headache



Subdural Hemorrhage

- Venous Bleeding
- High Risk Populations:
 - Elderly
 - Alcoholic
 - Blood thinners
- Can accumulate slowly

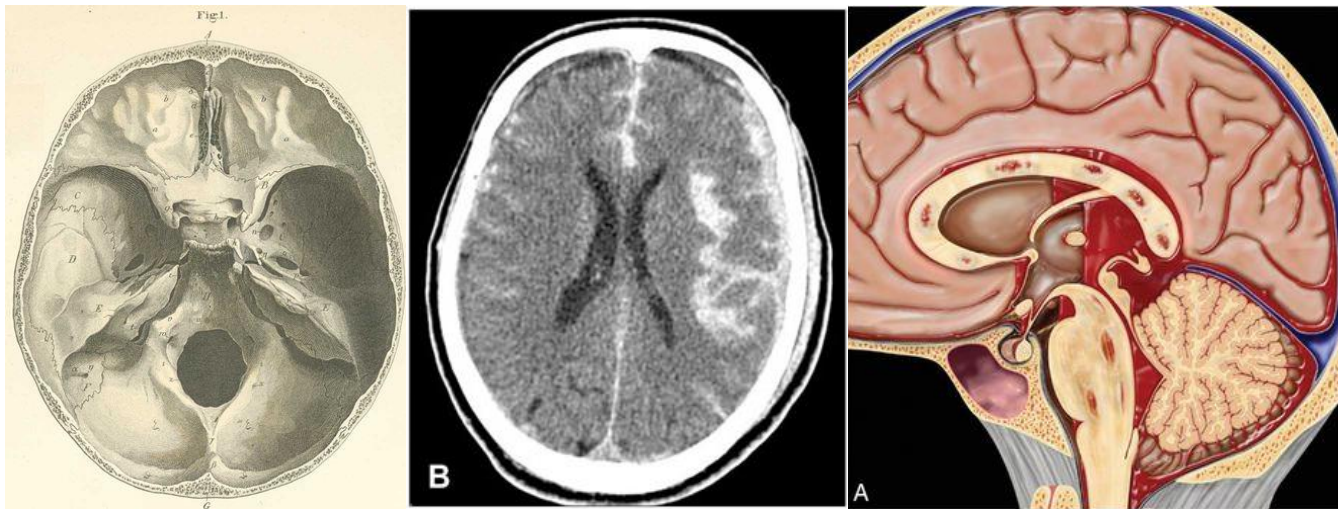


Worsening headache leading to altered mental status

Traumatic Subarachnoid Hemorrhage

Venous shear injury

Blood tracks in and out of sulci



Rarely requires surgery

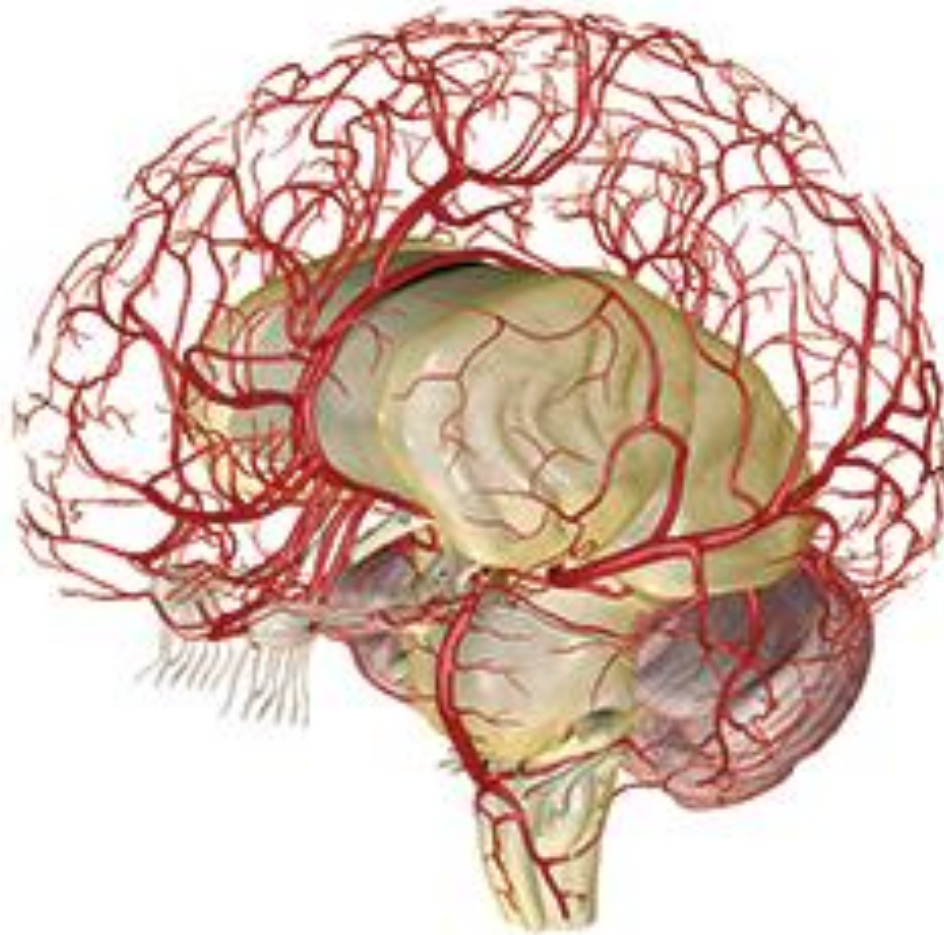Concussion / Traumatic Brain Injury

- Headaches
- Dizziness
- Confusion
- Nausea
- Blurry Vision



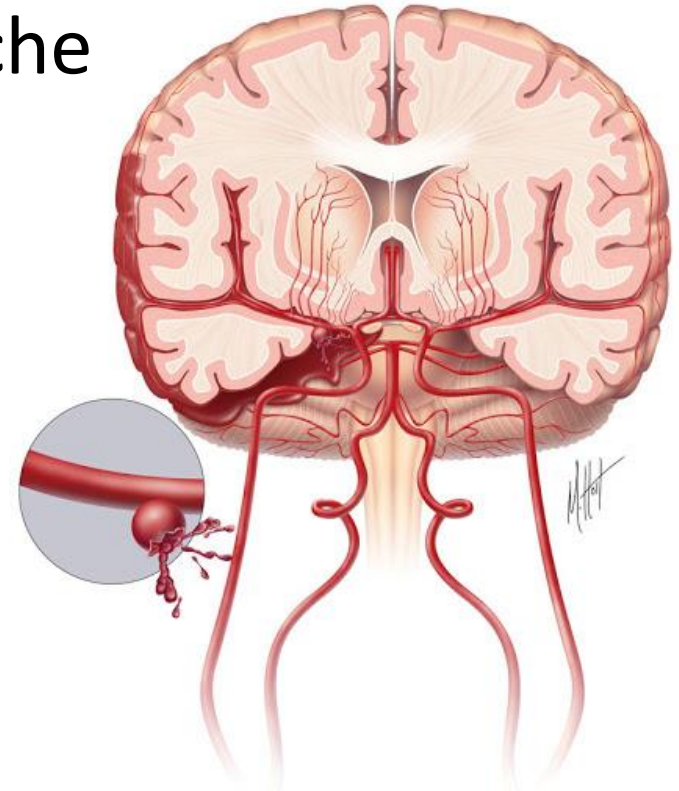
Post-Concussive symptoms can last for months

Vascular Causes of Headache



Spontaneous Subarachnoid Hemorrhage

- Severe sudden onset headache
 - “Worst headache of my life”
 - May cause seizures, N/V
 - Stroke-like symptoms
 - Declining mental status
- Usually <50 years old
- Mortality approaches 40%

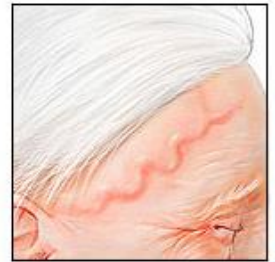

**Usually caused by
aneurysm or vascular
malformation**

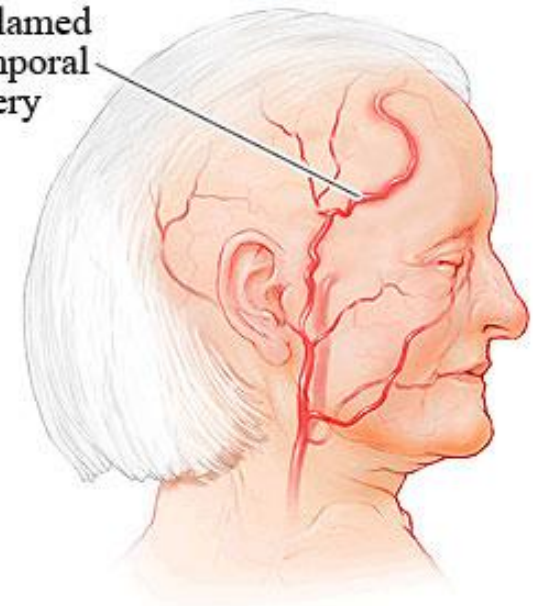
Temporal Arteritis

- Vasculitis, or blood vessel inflammation
- Unilateral, severe, throbbing headache
 - Jaw pain
 - Tender to palpation
 - Fever or flu like symptoms
 - Vision changes or loss
- More common in females >50
 - Average age is 72 years old

Giant cell arteritis

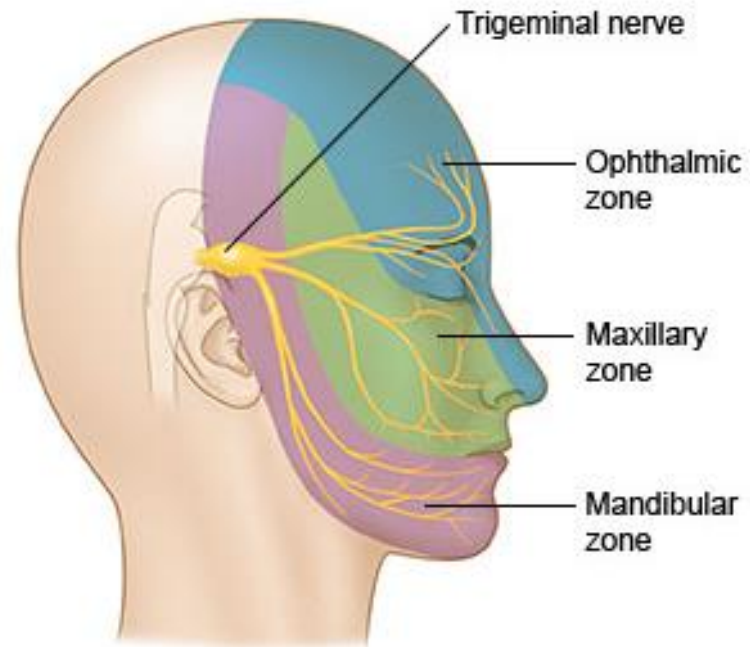


Inflamed temporal artery



Trigeminal Neuralgia

- Severe sharp, electrical facial pain in Trigeminal nerve distribution
 - Chewing
 - Talking
 - Brushing teeth
 - Facial touch
- Nerve pressure or inflammation:
 - Multiple Sclerosis
 - Basilar artery aneurysm
 - Acoustic schwannoma
 - Posterior fossa meningioma



Venous Sinus Thrombosis

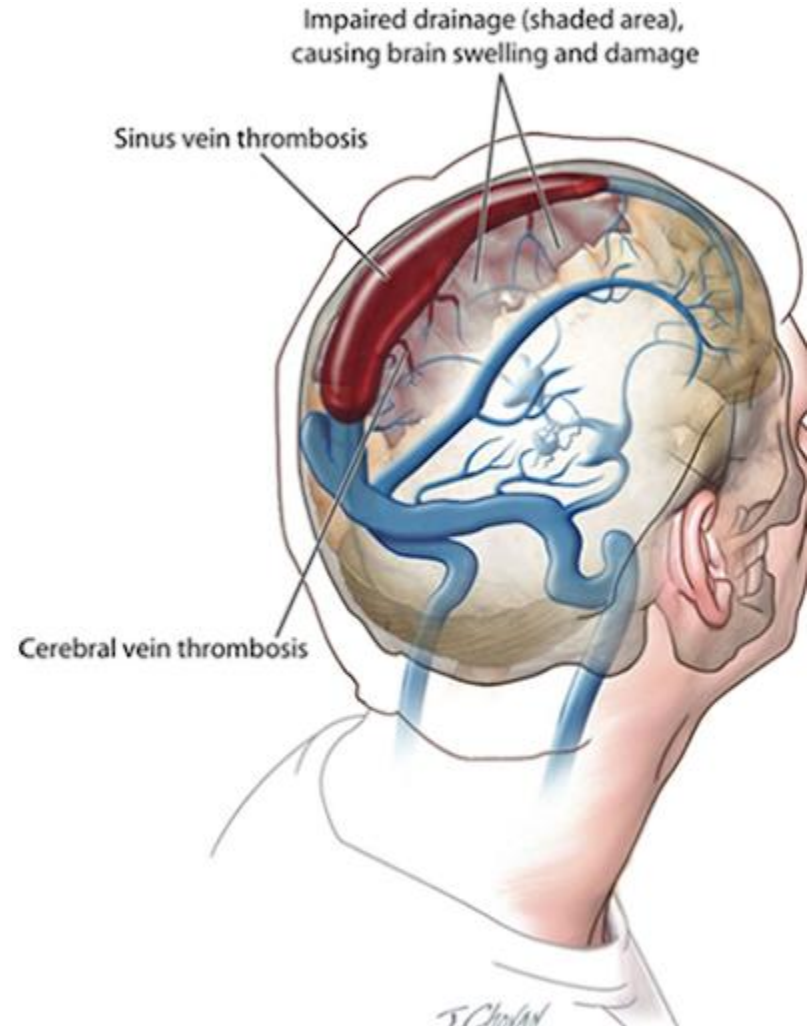
Blood clot in the veins that drain the brain

- Common presentations:

- Headache
- Vision changes
- Vomiting
- Seizure
- Stroke like symptoms

- Risk Factors:

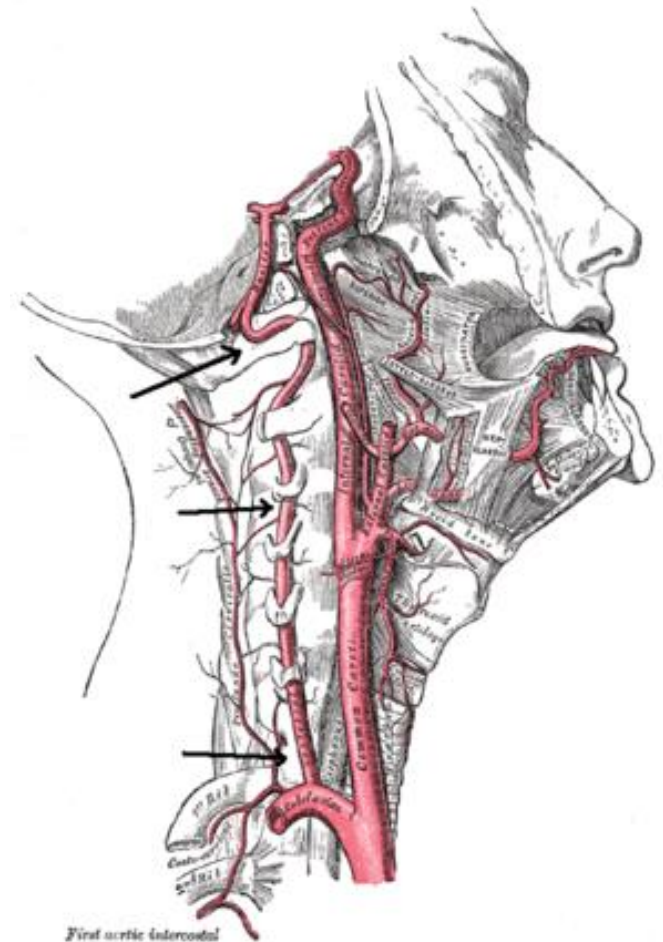
- Clotting disorder
- Extra estrogen (birth control)
- Infections
- Trauma



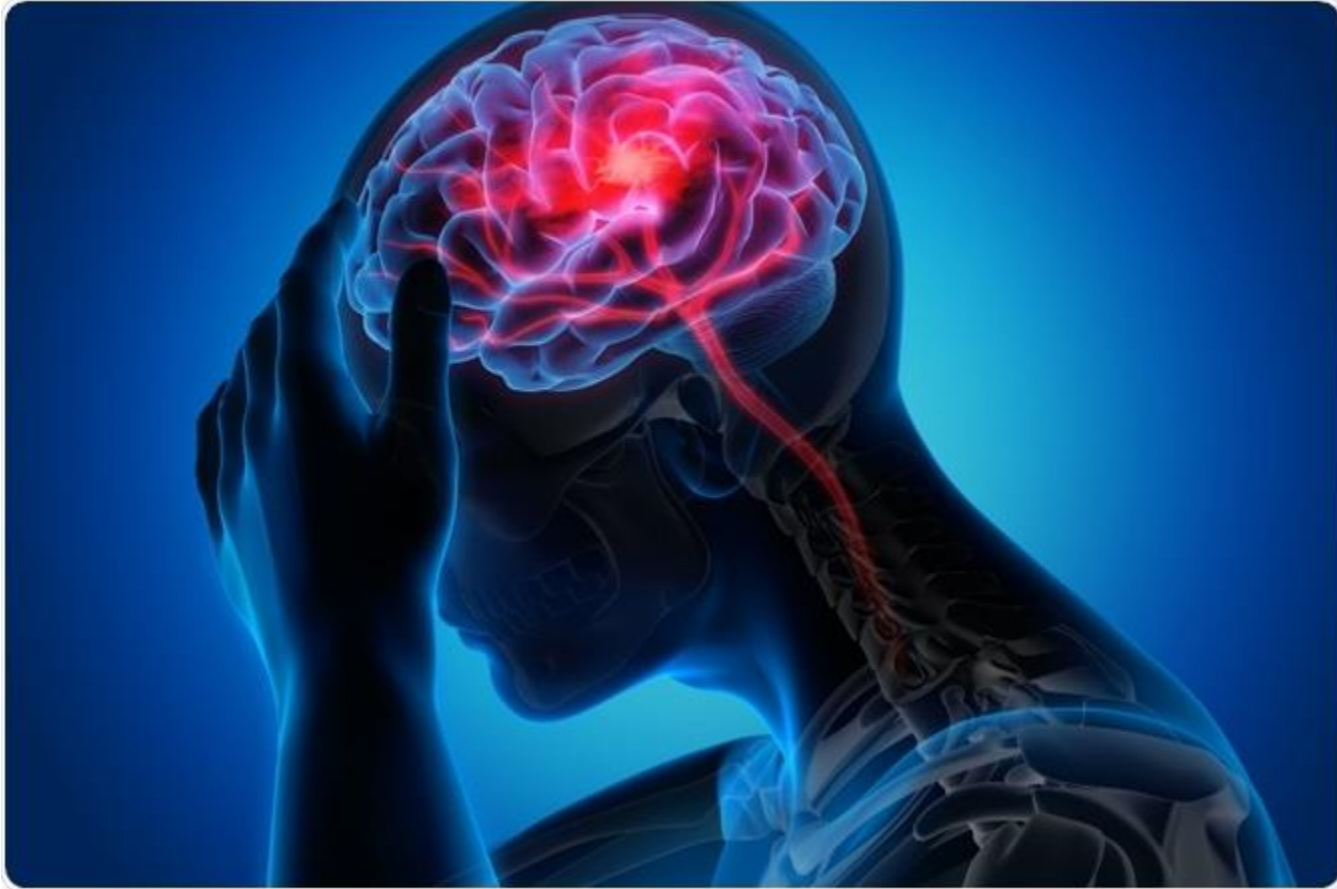Cervical Artery Dissection

A Flap-Like Tear In The Artery Wall

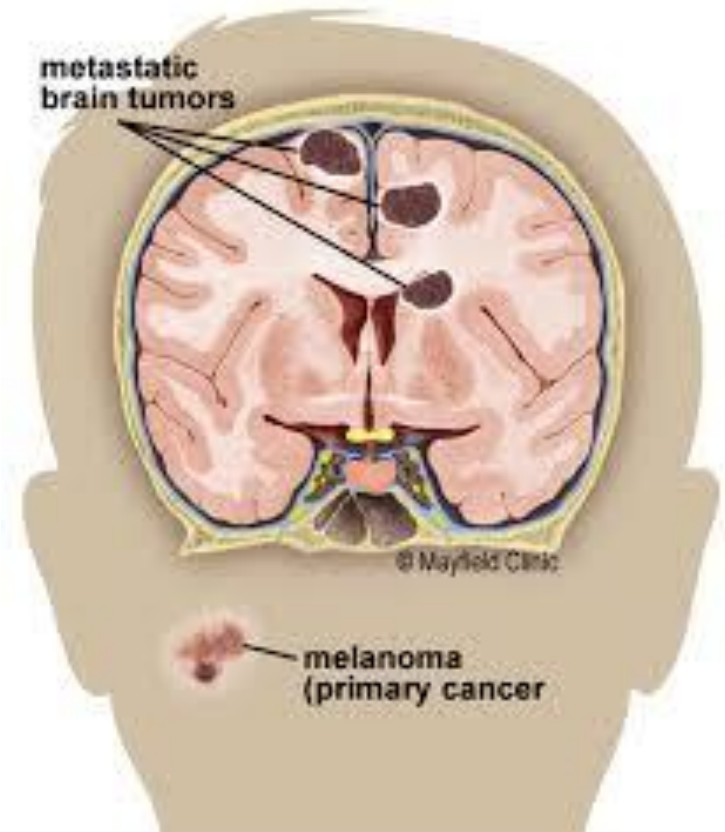
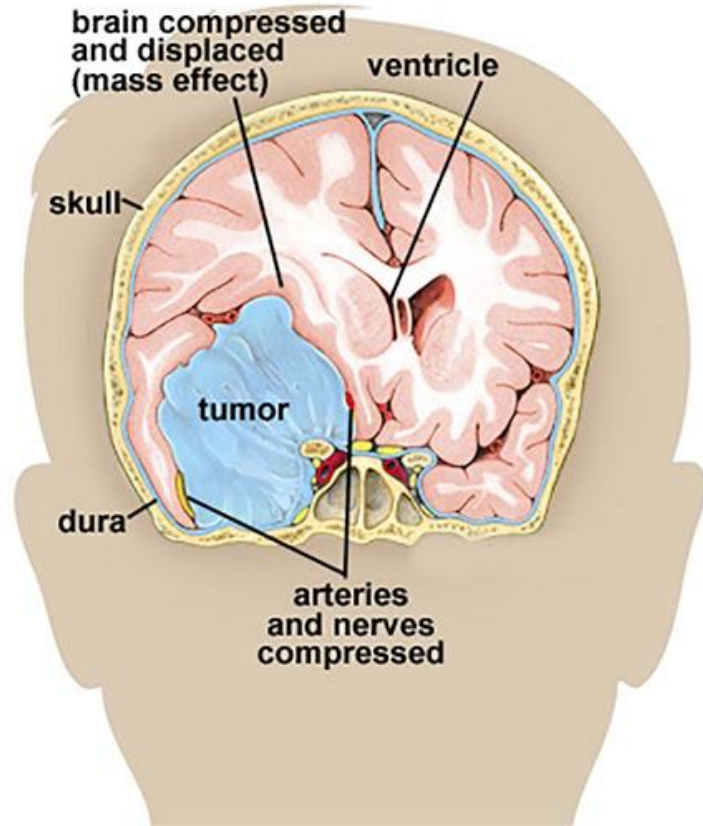
- Common Presentations:
 - Headache
 - Neck Pain
 - Stroke Like Symptoms
 - Vision Changes
- Causes:
 - Chiropractors
 - Sports
 - Trauma
 - Strangulation
 - Spontaneous



Elevated Intracranial Pressure



Brain Tumor Or Metastasis



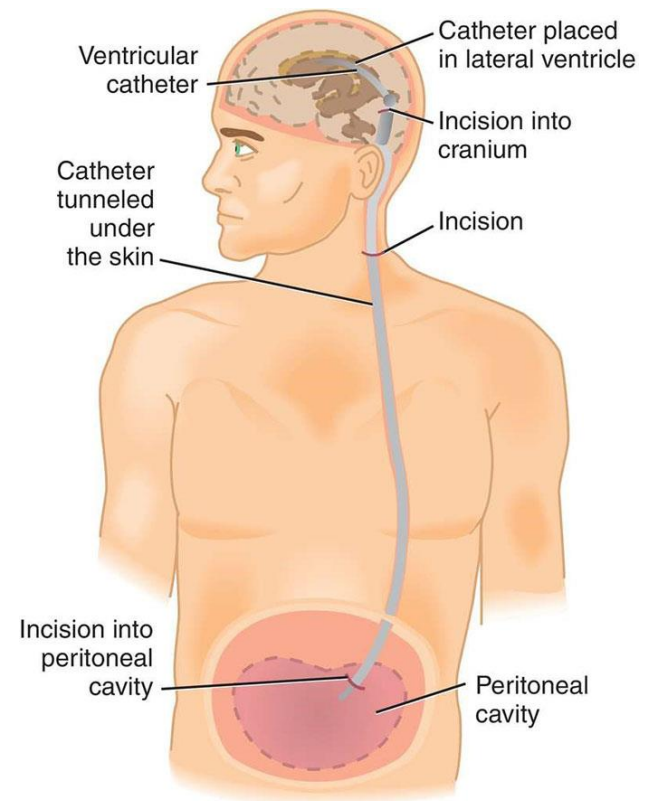
Most brain tumors are metastatic.

Ask about melanoma, lung, breast, colon cancer history

Ventriculo-Peritoneal (VP) Shunt

Drains cerebrospinal fluid from brain to decrease intracranial pressure

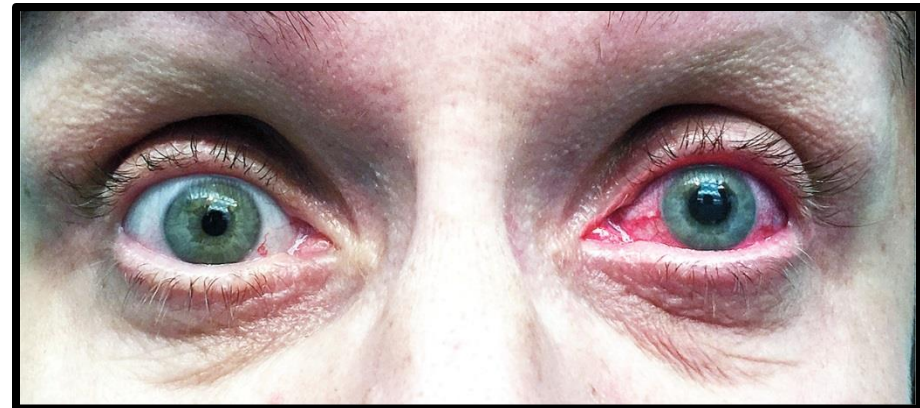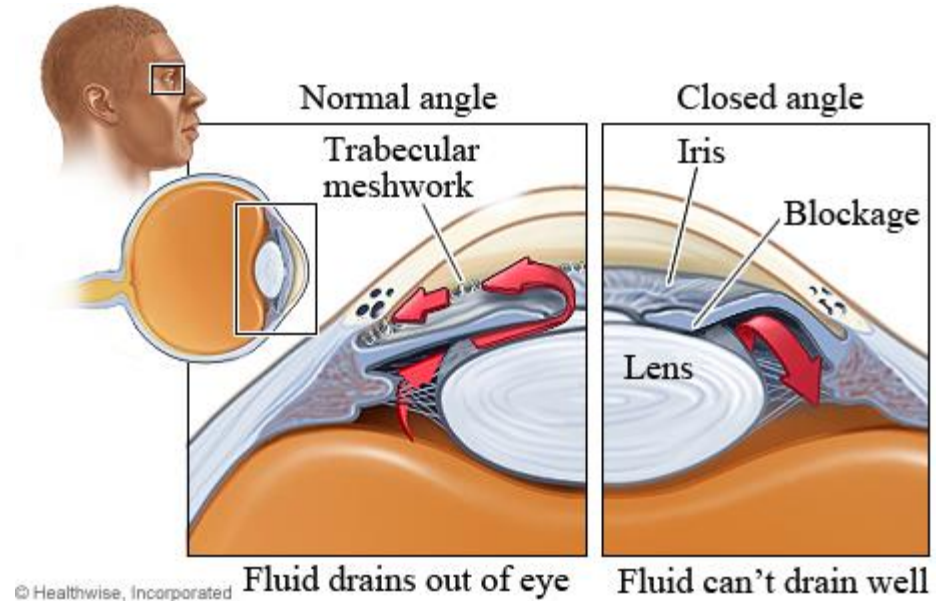
- Complications include:
 - Infection
 - Disruption of hardware
 - Over-Drainage
 - Bleeding
- Can cause headache, vomiting, altered mental status



Acute Angle Closure Glaucoma

Common Presentations:

- Sudden, severe eye pain
- Headache
- Vomiting



Mid-dilated non-responsive pupil, red eye, corneal haze

Pre-Eclampsia

BP > 140/90 On Two Occasions During Pregnancy

- Nulliparous
- Previous preeclampsia
- Multiple Gestation
- Abnormal Placentation

Immunogenic
Related



- Chronic HTN
- Chronic Renal Disease
- Collagen Vascular Disease
- Pregestational DM

Disease
Related



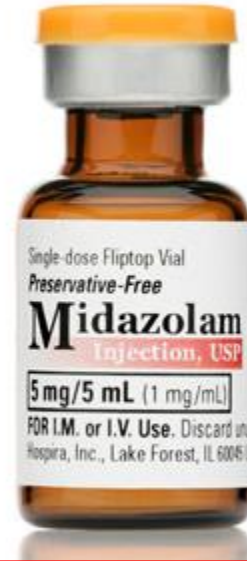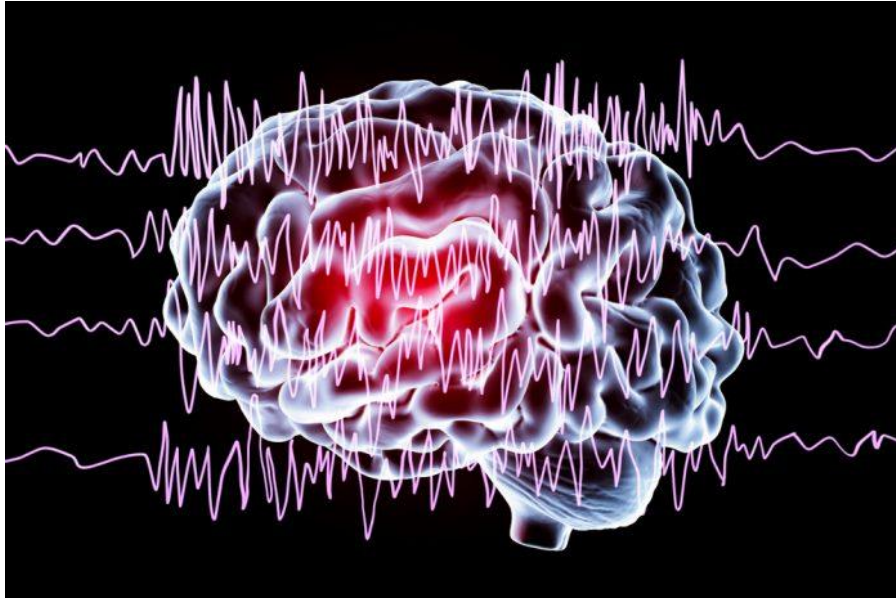
- African American
- Obesity
- 35 < Age < 20
- New paternity
- Cohabitation < 1 year

Maternal
Related

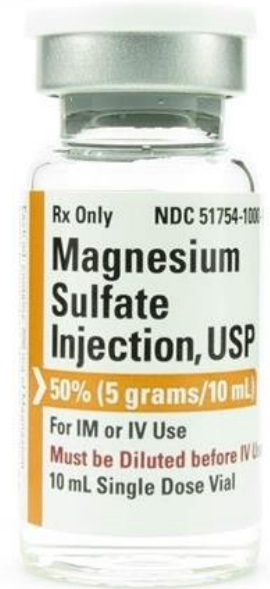

Can cause headaches, vision changes, edema, shortness of breath

Eclampsia = Seizure



**1-5mg IV/IO/IM/IN
Q3-5 min to max 10mg**



**4 grams IV/IO
Over 10 min**

Can Occur Up To 12 Weeks After Delivery

Toxicity/Environmental



Ask about exposures

Carbon Monoxide

- Headache
- Dizziness
- Confusion
- Flu like illness



Rainbow probe on
Lifepack will give a
CO level



- 1. Protect yourself**
- 2. Remove patient**
- 3. Treat with high flow O2**



Environment Altitude and Dehydration



Types of Headaches

Primary


- Migraine
- Tension
- Cluster

Secondary

- Infection
- Trauma
- Vascular
- Tumor
- Toxicity

Ask About These Red Flags

1. Recent Head Trauma
2. History of cancer
3. Bleeding/clotting disorder
4. Associated Symptoms:
 - Fever , Neck stiffness
 - Vision changes
 - New neuro symptoms
5. Onset and progression of pain



EMS Treatment of Headache

- Airway and Oxygen if indicated
- Pain control
 - Narcotics?
 - No NSAIDS
 - Tylenol
 - Ketamine
 - Droperidol
- Anti-emetics
- IV fluids



Questions??
